

OPEN ACCESS



African Journal of
Pharmacy and Pharmacology

15 February 2018

ISSN 1996-0816

DOI: 10.5897/AJPP

www.academicjournals.org

academicJournals



Academic
Journals

ABOUT AJPP

The **African Journal of Pharmacy and Pharmacology (AJPP)** is published weekly (one volume per year) by Academic Journals.

African Journal of Pharmacy and Pharmacology (AJPP) is an open access journal that provides rapid publication (weekly) of articles in all areas of Pharmaceutical Science such as Pharmaceutical Microbiology, Pharmaceutical Raw Material Science, Formulations, Molecular modeling, Health sector Reforms, Drug Delivery, Pharmacokinetics and Pharmacodynamics, Pharmacognosy, Social and Administrative Pharmacy, Pharmaceutics and Pharmaceutical Microbiology, Herbal Medicines research, Pharmaceutical Raw Materials development/utilization, Novel drug delivery systems, Polymer/Cosmetic Science, Food/Drug Interaction, Herbal drugs evaluation, Physical Pharmaceutics, Medication management, Cosmetic Science, pharmaceuticals, pharmacology, pharmaceutical research etc. The Journal welcomes the submission of manuscripts that meet the general criteria of significance and scientific excellence. Papers will be published shortly after acceptance. All articles published in AJPP are peer-reviewed.

Contact Us

Editorial Office: ajpp@academicjournals.org

Help Desk: helpdesk@academicjournals.org

Website: <http://www.academicjournals.org/journal/AJPP>

Submit manuscript online <http://ms.academicjournals.me/>

Editors

Himanshu Gupta

*Department of Pharmacy Practice
University of Toledo
Toledo, OH
USA.*

Prof. Zhe-Sheng Chen

*College of Pharmacy and Health Sciences
St. John's University
New York,
USA.*

Dr. Huma Ikram

*Neurochemistry and Biochemical
Neuropharmacology Research Unit,
Department of Biochemistry,
University of Karachi
Karachi-75270
Pakistan*

Dr. Shreesh Kumar Ojha

*Molecular Cardiovascular Research Program
College of Medicine
Arizona Health Sciences Center
University of Arizona
Arizona,
USA.*

Dr. Vitor Engracia Valenti

*Departamento de Fonoaudiologia
Faculdade de Filosofia e Ciências,
UNESP
Brazil.*

Dr. Caroline Wagner

*Universidade Federal do Pampa
Avenida Pedro Anunciação
Brazil.*

Dr. Ravi Shankar Shukla

*Macromolecule and Vaccine Stabilization Center
Department of Pharmaceutical Chemistry
University of Kansas
USA.*

Associate Editors

Dr. B. Ravishankar

*SDM Centre for Ayurveda and Allied Sciences,
SDM College of Ayurveda Campus,
Karnataka
India.*

Dr. Natchimuthu Karmegam

*Department of Botany,
Government Arts College,
Tamil Nadu,
India.*

Dr. Manal Moustafa Zaki

*Department of Veterinary Hygiene and
Management
Faculty of Veterinary Medicine,
Cairo University
Giza,
Egypt.*

Prof. George G. Nomikos

*Takeda Global Research & Development Center
USA.*

Prof. Mahmoud Mohamed El-Mas

*Department of Pharmacology,
Faculty of Pharmacy
University of Alexandria,
Alexandria,
Egypt.*

Dr. Kiran K. Akula

*Electrophysiology & Neuropharmacology Research
Unit
Department of Biology & Biochemistry
University of Houston
Houston, TX
USA.*

Editorial Board

Prof. Fen Jicai

School of life science, Xinjiang University, China.

Dr. Ana Laura Nicoletti Carvalho

Av. Dr. Arnaldo, 455, São Paulo, SP. Brazil.

Dr. Ming-hui Zhao

*Professor of Medicine
Director of Renal Division, Department of Medicine
Peking University First Hospital
Beijing 100034
PR. China.*

Prof. Ji Junjun

Guangdong Cardiovascular Institute, Guangdong General Hospital, Guangdong Academy of Medical Sciences, China.

Prof. Yan Zhang

Faculty of Engineering and Applied Science, Memorial University of Newfoundland, Canada.

Dr. Naoufel Madani

*Medical Intensive Care Unit
University hospital Ibn Sina, Univesity Mohamed V Souissi, Rabat, Morocco.*

Dr. Dong Hui

Department of Gynaecology and Obstetrics, the 1st hospital, NanFang University, China.

Prof. Ma Hui

School of Medicine, Lanzhou University, China.

Prof. Gu HuiJun

School of Medicine, Taizhou university, China.

Dr. Chan Kim Wei

*Research Officer
Laboratory of Molecular Biomedicine, Institute of Bioscience, Universiti Putra, Malaysia.*

Dr. Fen Cun

Professor, Department of Pharmacology, Xinjiang University, China.

Dr. Sirajunnisa Razack

Department of Chemical Engineering, Annamalai University, Annamalai Nagar, Tamilnadu, India.

Prof. Ehab S. EL Desoky

Professor of pharmacology, Faculty of Medicine Assiut University, Assiut, Egypt.

Dr. Yakisich, J. Sebastian

*Assistant Professor, Department of Clinical Neuroscience R54
Karolinska University Hospital, Huddinge
141 86 Stockholm , Sweden.*

Prof. Dr. Andrei N. Tchernitchin

*Head, Laboratory of Experimental Endocrinology and Environmental Pathology LEEPA
University of Chile Medical School, Chile.*

Dr. Sirajunnisa Razack

Department of Chemical Engineering, Annamalai University, Annamalai Nagar, Tamilnadu, India.

Dr. Yasar Tatar

Marmara University, Turkey.

Dr Nafisa Hassan Ali

*Assistant Professor, Dow institute of medical technology
Dow University of Health Sciences, Chand bbi Road, Karachi, Pakistan.*

Dr. Krishnan Namboori P. K.

Computational Chemistry Group, Computational Engineering and Networking, Amrita Vishwa Vidyapeetham, Amritanagar, Coimbatore-641 112 India.

Prof. Osman Ghani

University of Sargodha, Pakistan.

Dr. Liu Xiaoji

School of Medicine, Shihezi University, China.

ARTICLE

Isolation, structure elucidation, antioxidant and hepatoprotective effects of petroleum ether extract of *Artemisia integrifolia* L. against CCl₄-induced liver injury in rats

80

BAO Ha-Si-E-Er-Dun, WANG Qing-Hu, BA E-Er-Dun-Bu-La-Ga and XU Yan-Hua

Full Length Research Paper

Isolation, structure elucidation, antioxidant and hepatoprotective effects of petroleum ether extract of *Artemisia integrifolia* L. against CCl₄-induced liver injury in rats

BAO Ha-Si-E-Er-Dun¹, WANG Qing-Hu^{2*}, BA E-Er-Dun-Bu-La-Ga² and XU Yan-Hua²¹Affiliated Hospital, Inner Mongolia University for Nationalities, Tongliao 028000, Inner Mongolia, China.²College of Traditional Mongolian Medicine, Inner Mongolia University for Nationalities, Tongliao 028000, China.

Received 10 December, 2017; Accepted 2 January, 2018

The aim of this study was to investigate the chemical constituents of petroleum ether extract from *Artemisia integrifolia* L (AIPEE) and to evaluate its hepatoprotective potential and *in vivo* antioxidant effects. Six compounds, namely eugenol (1), linolenic acid (2), 6,7-epoxy-linolenic acid (3), linoleic acid (4), oleic acid (5) and hexadecanoic acid (6) were isolated from the AIPEE. Oral administration of AIPEE significantly reduced carbon tetrachloride-induced elevations in the levels of plasma markers of hepatic damage and lipid peroxidation. It also rescued histopathologic alterations observed in the liver and levels of oxidative stress markers. AIPEE exhibited antioxidant and hepatoprotective activities *in vivo*, which may be attributable to its chemical constituents such as five fatty acids and eugenol.

Key words: *Artemisia integrifolia* L., fatty acids, eugenol, antioxidant, hepatoprotection.

INTRODUCTION

Liver is the most important organ, which is involved in several vital functions, for example, metabolism, secretion and storage (Sharma et al., 2012; Mistry et al., 2013). It has great capacity to detoxicate toxic substances and synthesize useful principles. Thus, excessive exposure to drugs and environmental pollutants overpower the detoxification mechanisms of the liver and lead to liver injury (Setty et al., 2007).

Oxidative stress, an important factor that induces liver fibrosis, represents a key feature of hepatitis induced by various conditions, including anoxic/reoxygenation injury,

autoimmune hepatitis, viral hepatitis, and alcoholic hepatitis (Singh et al., 2008). The CCl₄-induced liver toxicity model is widely used because CCl₄ induces hepatic changes analogous to those observed in chemical hepatitis. In the liver, CCl₄ is converted by the cytochrome P450 system into a trichloromethyl radical. This radical reacts with oxygen to form a trichloromethylperoxyl radical, which reacts with cell macromolecules, inducing lipid peroxidation and provoking hepatocyte membrane breakdown (Halliwell, 2012).

*Corresponding author. E-mail: wqh196812@163.com. Tel: +86-0475-8314242. Fax: +86-0475-8314242.

Liver damage is associated with lipid peroxidation, enzyme leakage, and depletion in the GSH level (Singh et al., 2008). Chronic liver injury may develop into several liver diseases, including hepatic steatosis, fibrosis, cirrhosis, and hepatocellular carcinoma (Srivastava and Shivanandappa, 2010). Conventional or synthetic drugs used in the treatment of liver diseases are sometimes inadequate and can have serious adverse effects (Liu et al., 2006). On the other hand, Mengyixue, an indigenous system of medicine in Inner Mongolia, has a long tradition of treating liver disorders with Mongolian medicine (Wang et al., 1998).

Artemisia integrifolia L., belonging to the family Compositae, is distributed throughout Inner Mongolia (Zhang et al., 2008). It is characteristic cuisine of Daur in Hulunbeier of Inner Mongolia, and is considered to be the green vegetables for possessing rich in nutrition and heat-clearing and detoxicating (Tu and Liu, 2007). In Mongolian medicine, *A. integrifolia* L. is cold in property, with a bitter flavor. It has been used as a folk medicine to treat cardiovascular disease and liver diseases (Zhang et al., 2008). The ethanol extract of *A. integrifolia* L. possess very good *in vitro* superoxide, hydroxyl and nitric oxide radical scavenging, and lipid peroxidation inhibiting activities (Liu et al., 2010). The phytochemical screening of the plant extract showed the presence of flavonoids, coumarin, amino acids and proteins (Hu and Feng, 1999). However, up to date, there have been few studies about the hepatoprotective effects of *A. integrifolia* L.

In the paper, a systematic research was undertaken to investigate the chemical constituents of petroleum ether extract from *A. integrifolia* L (AIPEE) and to evaluate its hepatoprotective potential and *in vivo* antioxidant effects.

MATERIALS AND METHODS

The UV spectra were recorded on a Shimadzu UV-2201 spectrometer (Shimadzu, Japan). NMR spectra were measured on a Bruker Avance III-500 NMR spectrometer (Bruker, Germany) with tetramethylsilane (TMS) as the internal reference, and chemical shifts are expressed in δ (ppm). Semipreparative HPLC was performed by using a Japanese liquid chromatograph equipped with a EZ0566 column. Column chromatography was performed by using silica gel (200-300 mesh, Marine Chemical Factory, Qingdao, China).

Commercial assay kits for alanine aminotransferase (ALT), aspartate aminotransferase (AST), bilirubin (TB), superoxide dismutase (SOD), catalase (CAT), reduced glutathione (GSH), glutathione peroxidase (GPx) were purchased from Nanjing Jiancheng Bioengineering Institute (Nanjing, China). Silymarin was obtained from Ningbo Liwah Pharmaceutical Co. (Ningbo, China). Corn oil was purchased from Martha supermarket (Tongliao, China). High-performance liquid chromatography (HPLC)-grade acetonitrile was purchased from Merck (Darmstadt, Germany). All other chemicals and reagents were analytical grade.

Plant material

The aerial part of *A. integrifolia* L. were collected in Hailaer (126°04' E and 48°20' N), Hulunbeier, Inner Mongolia of China, in April 2015,

and identified by Prof. Buhebateer (Inner Mongolia University for Nationalities). The aerial part of *A. integrifolia* L. were placed in the shade to dry. A voucher (NO. 20150410) has been deposited in a warehouse (10-30°C, 30-50% RH, 24 h dark) in the School of Traditional Mongolian Medicine of Inner Mongolia University for Nationalities.

Extraction and isolation

The air dried aerial part of *A. integrifolia* L (2.0 Kg) were powdered and extracted twice under reflux petroleum ether (30 L). Evaporation of the solvent under reduced pressure (0.1 MPa) delivered the petroleum ether extract (965 g). The AIPEE was stored in a refrigerator (0-4°C) for further use.

The AIPEE (30 g) was separated by column chromatography on silica gel and gradiently eluted with petroleum ether-ethyl acetate (80:1 to 20:1) to give 4 fractions (Fractions 1-4). Fraction 2 [210 mg, petroleum ether-ethyl acetate (60:1) elute] was subjected to silica gel column chromatography using petroleum ether-ethyl acetate with increasing polarity (70: 1-50: 1) to give 1 (18 mg) and 2 (43 mg); Fraction 3 [330 mg, petroleum ether-ethyl acetate (40:1) elute] was separated by semipreparative HPLC [The separation was performed on EZ0566 column (250 mm × 4.6 mm, 5 μ m) with acetonitrile-water (85:15) as the mobile phase and a detection wavelength at 215 nm (Figure 1). The retention time of compounds 6, 5, 4 and 3 were 10.02, 13.52, 16.21 and 18.02 min, respectively] yielding 6 (17 mg), 5 (22 mg), 4 (24 mg) and 3 (37 mg).

Animals and experimental design

Wistar rats (200-300 g) were provided by Changchun Yisheng Laboratory Animal Technology Co., Ltd. (Changchun, China). The rats were maintained under standard animal housing conditions (25 ± 5°C, 40-70% RH, 12 h light/dark cycle) and provided with standard laboratory food (Rat sterile granulated feed, product executive standard: GB14924-2001, license: SCXK-(JI) 2010-0001) and water *ad libitum*. All procedures were performed in accordance with National Institute of Health guidelines for the care and use of animals and approved by the Institute Animal Care and Use Committee (IACUC. Approved num: 20120228). Rats were randomly assigned to six experimental groups (n = 10), as described later. CCl₄ was administered intraperitoneally (i.p.) at a single dose of 3 mL/kg, diluted in corn oil (vehicle 50%, v/v) to animals in groups 2 to 6: Group 1: Control, received 2.0 mL/kg i.p. of vehicle; Group 2: toxicant (CCl₄, 3.0 mL/kg, i.p.) (Milena et al., 2014); Group 3: CCl₄ + AIPEE for 7 d (100 mg/kg, p.o.); Group 4: CCl₄ + AIPEE for 7 d (200 mg/kg, p.o.); Group 5: CCl₄ + AIPEE for 7 d (300 mg/kg, p.o.); Group 6: CCl₄ + Legalon for 7 d (300 mg/kg, p.o.).

AIPEE and Legalon were administered by gastric gavages daily for 7 d starting 24 h after CCl₄-induced liver injury. Legalon was used as a standard drug.

Collection and processing of tissue sample

On day 8, animals were anaesthetized (30 mg/kg, i.p. of chloral hydrate), sacrificed by cervical dislocation, and submitted to laparotomy. Blood was collected from abdominal artery into non-heparinized tubes and centrifuged at 4°C, 900 rpm for 10 min to obtain serum for biochemical tests. The livers were quickly excised, washed, and used to determine the levels of the oxidative stress markers (thiobarbituric acid reactive substance [TBARS], SOD, CAT, GPx, and GSH) and for histopathologic studies. All determinations were performed in triplicate.

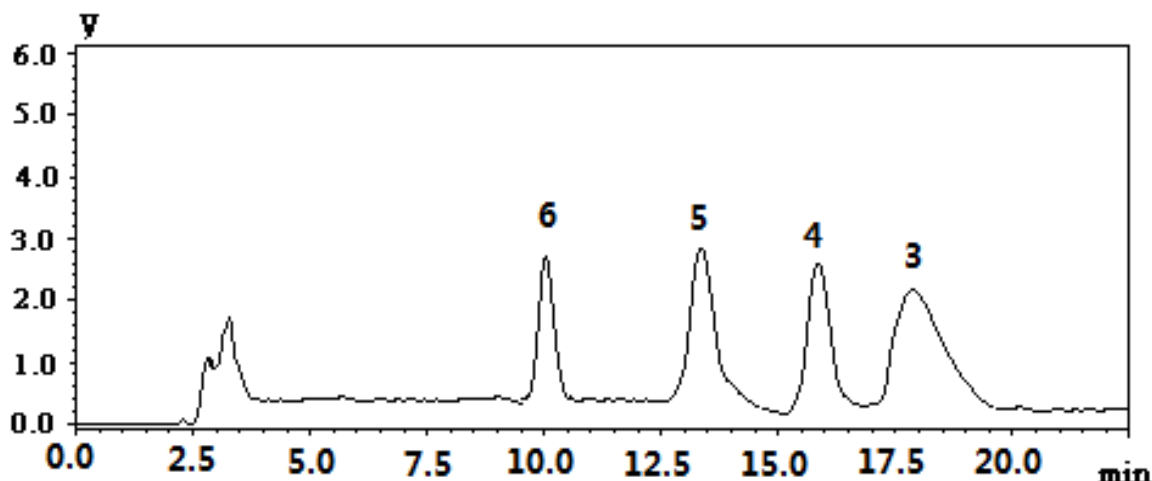


Figure 1. HPLC chromatogram of compounds 3-6 from Fraction 3.

Preparation of tissue homogenate

Hepatic tissues were homogenized in cold 50 mM potassium phosphate buffer (pH 7.0) using a Potter-Elvehjem homogenizer to give a 10% (w/v) liver homogenate and centrifuged at 600 rpm for 5 min. The filtrate was used for further estimations.

Serum parameters

AST, ALT, and TB levels were analyzed to assess hepatic function using Biosystems kits, according to the manufacturer's instructions.

Oxidative stress analyses (Das et al., 2000)

The liver homogenate was used to analyze the enzymatic antioxidant activities by SOD, CAT, GPx, and nonenzymatic antioxidants like GSH were evaluated in liver tissue homogenate by respective methods. TBARS levels were determined by a previously described method.

Histopathologic analysis

For histological studies, the liver tissues were fixed with 10% phosphate buffered neutral formalin, dehydrated in graded (50%–100%) alcohol and embedded in paraffin. Thin sections (5 μ m) were cut and stained with routine hematoxylin and eosin (H&E) stain for photo microscopic assessment. The initial examination was qualitative, with the purpose of determining histopathological lesions in liver.

Acute toxicity

For the assessment of acute toxicity, wistar rats (200–300 g) were divided into three groups of 10 animals. The AIPEE and legalon were given p.o. at the doses of 1500 mg/kg to the group 2 and group 3, respectively. The control group (group 1) received p.o. received 2.0 mL/kg i.p. of vehicle. The mortality rate within 72 h period was determined and the LD₅₀ was estimated according to the method described by references (Silva et al., 2005).

Statistical analysis

Data, expressed as the mean \pm SD, were analyzed by one-way analysis of variance and Tukey-Kramer posthoc tests using GraphPad Software version 4.0. $P < 0.05$ was considered significant.

RESULTS

AIPEE was separated by chromatography and assigned six compounds, namely eugenol (1), linolenic acid (2), 6,7-epoxy-linolenic acid (3), linoleic acid (4), oleic acid (5) and hexadecanoic acid (6) (Figure 2). The structures of the compounds were identified by comparing their spectroscopic data with those reported in the literature (Wang et al., 2010; Yang et al., 2008; Deng et al., 2013; Zan et al., 2008).

Eugenol (1): Yellowish liquid; UV (hexane) λ_{max} (nm): 280; IR (KBr) ν_{max} (cm^{-1}): 3351, 1635, 1591, 1487 and 1201 cm^{-1} ; 1H -NMR (500MHz, $CDCl_3$) δ_H : 7.06 (1H, d, $J = 2.0$ Hz, H-2), 6.94 (1H, d, $J = 8.0$ Hz, H-5), 7.10 (1H, dd, $J = 8.0, 2.0$ Hz, H-6), 2.07 (2H, m, H-7), 5.81 (1H, m, H-8), 5.95 (2H, m, H-9), 3.78 (3H, s, $-OCH_3$). ^{13}C -NMR (125MHz, $CDCl_3$) δ_C : 126.7 (C-1), 109.3 (C-2), 148.5 (C-3), 146.8 (C-4), 114.1 (C-5), 123.5 (C-6), 41.2 (C-7), 145.7 (C-8), 110.2 (C-9), 56.1 ($-OCH_3$).

Linolenic acid (2): Colorless oily liquid. 1H -NMR (500MHz, $CDCl_3$) δ_H : 2.34 (2H, t, $J = 7.5$ Hz, H-2), 1.62 (2H, m, H-3), 1.31-1.35 (8H, m, H-4-7), 2.05 (2H, m, H-8), 2.80 (4H, t, $J = 6.5$ Hz, H-11, 14), 5.42-5.35 (6H, m, H-9, 10, 12, 13, 15, 16), 2.07 (2H, q, $J = 7.5$ Hz, H-17), 0.96 (3H, t, $J = 7.5$ Hz, H-18). ^{13}C -NMR (125MHz, $CDCl_3$) δ_C : 80.3 (C-1), 34.1 (C-2), 24.6 (C-3), 29.0 (C-4, 7), 29.1 (C-5), 29.6 (C-6), 27.6 (C-8), 130.2 (C-9), 127.8 (C-10), 25.6 (C-11), 128.2 (C-12), 128.3 (C-13), 25.5 (C-14), 127.1 (C-15), 131.9 (C-16), 20.6 (C-17), 14.3 (C-18). 6,7-epoxy-linolenic acid (3). Colorless oily liquid. 1H -NMR

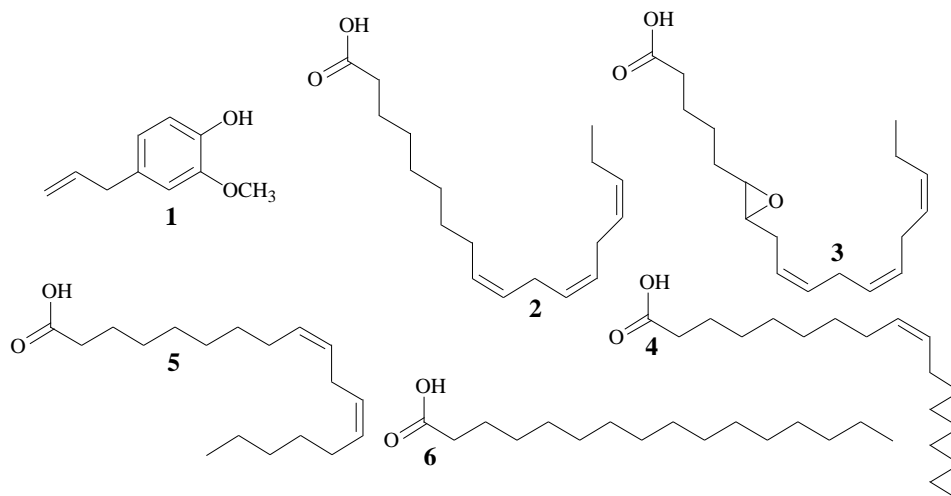


Figure 2. Structures of isolated compounds 1-6.

Table 1. Effect of AIPEE on serum biochemical parameters in CCl₄-treated rats.

Particulars	Group 1	Group 2	Group 3	Group 4	Group 5	Group 6
Relative weight (%) liver	3.41 ± 0.22	4.43 ± 0.47 ^a	4.02 ± 0.34 ^b	3.63 ± 0.48 ^{##}	3.29 ± 0.32 ^{###}	3.34 ± 0.50 ^{###}
ALT (U/L)	48 ± 18	378 ± 49 ^a	303 ± 38 ^{a#}	125 ± 42 ^{b##}	50 ± 21 ^{###}	53 ± 13 ^{###}
AST(U/L)	124 ± 29	718 ± 142 ^a	542 ± 81 ^{a#}	358 ± 69 ^{b##}	109 ± 32 ^{###}	127 ± 26 ^{###}
TB (mg/dL)	1.22 ± 0.18	2.71 ± 0.42 ^a	2.07 ± 0.19 ^a	1.89 ± 0.31 ^{b##}	1.28 ± 0.24 ^{###}	1.30 ± 0.20 ^{###}

Values are expressed as the means ± SD; ^a P < 0.001, ^b P < 0.01 and ^c P < 0.05) compared with Group 1; [#] P < 0.01 and ^{##} P < 0.05) compared with control group.

(500MHz, CDCl₃) δ_H: 2.34 (2H, t, J = 7.5 Hz, H-2), 1.61 (2H, m, H-3), 1.33 (2H, m, H-4), 2.01 (2H, m, H-5), 4.28 (1H, m, H-6), 4.30 (1H, m, H-7), 2.08 (2H, m, H-8), 2.78 (4H, t, J = 6.5 Hz, H-11, 14), 5.38-5.32 (6H, m, H-9, 10, 12, 13, 15,16), 2.05 (2H, q, J = 7.5 Hz, H-17), 0.90 (3H, t, J = 7.5 Hz, H-18). ¹³C-NMR (125MHz, CDCl₃) δ_C: 173.2 (C-1), 34.2 (C-2), 24.8 (C-3), 29.1 (C-4), 27.2 (C-5), 62.1 (C-6), 68.9 (C-7), 25.5 (C-8), 130.2 (C-9), 127.9 (C-10), 25.6 (C-11, 14), 128.2 (C-12), 128.3 (C-13), 127.1 (C-15), 131.9 (C-16), 20.6 (C-17), 14.1 (C-18).

Linoleic acid (4): Colorless oily liquid. ¹H-NMR (500MHz, CDCl₃) δ_H: 5.42-5.35 (4H, m, H-9, 10, 12, 13), 2.38 (2H, t, J = 7.5 Hz, H-2), 1.66 (2H, m, H-3), 1.31-1.33 (10H, m, H-4~7, 15), 2.08 (4H, t, J = 7.5 Hz, H-8, 14), 2.80 (2H, t, J = 6.5 Hz, H-11), 1.28 (2H, m, H-16), 1.34 (2H, m, H-17), 0.92 (3H, t, J = 6.5 Hz, H-18). ¹³C-NMR (125MHz, CDCl₃) δ_C: 179.7 (C-1), 34.0 (C-2), 24.7 (C-3), 29.0 (C-4), 29.2 (C-5), 29.1 (C-6), 29.4 (C-7), 27.3 (C-8), 128.1 (C-9), 130.2 (C-10), 25.6 (C-11), 127.9 (C-12), 130.0 (C-13), 27.1 (C-14), 29.4 (C-15), 31.5 (C-16), 22.6 (C-17), 14.1 (C-18).

Oleic acid (5): Colorless oily liquid. ¹H-NMR (500MHz, CDCl₃) δ_H: 5.40 (1H, d, J = 5.5 Hz, H-9), 5.34 (1H, d, J =

5.5 Hz, H-9), 2.37 (2H, t, J = 7.5 Hz, H-2), 1.65 (2H, m, H-3), 1.31-1.33 (16H, m, H-4~7, 12~15), 2.04 (4H, t, J = 7.5 Hz, H-8, 11), 1.28 (2H, m, H-16), 1.34 (2H, m, H-17), 0.92 (3H, t, J = 6.5 Hz, H-18). ¹³C-NMR (125MHz, CDCl₃) δ_C: 179.1 (C-1), 33.4 (C-2), 24.6 (C-3), 29.0 (C-4, 15), 29.6 (C-5, 6, 13,14), 29.2 (C-7, 12), 27.3 (C-8), 128.0 (C-9), 130.3 (C-10), 27.2 (C-11), 31.5 (C-16), 22.5 (C-17), 14.0 (C-18).

Hexadecanoic acid (6): Colorless oily liquid. ¹H-NMR (500MHz, CDCl₃) δ_H: 2.37 (2H, t, J = 7.5 Hz, H-2), 1.66 (2H, m, H-3), 1.28-1.32 (16H, m, H-4~13), 1.27 (2H, m, H-14), 1.34 (2H, m, H-15), 0.91 (3H, t, J = 6.5 Hz, H-16). ¹³C-NMR (125MHz, CDCl₃) δ_C: 179.4 (C-1), 33.9 (C-2), 24.7 (C-3), 29.0 (C-4, 13), 29.2 (C-5, 12), 29.6 (C-6, 7, 8, 9, 10, 11), 31.9 (C-14), 22.7 (C-15), 14.2 (C-16).

The levels of AST, ALT, and TB in serum were analyzed and the results are shown in Table 1. The oxidative stress analyses of liver homogenate are shown in Table 2. Figure 3 shows representative photomicrographs of livers obtained from different treatments.

No mortality was observed in groups of rats treated with the AIPEE and legalon. LD50 values for the AIPEE

Table 2. Effect of CCl₄, AIPEE and Legalon on CAT, SOD, GPx and GSH in rats.

Particulars	Group 1	Group 2	Group 3	Group 4	Group 5	Group 6
CAT (U/mg protein)	51.1 ± 12.2	16.5 ± 1.53 ^a	25.6 ± 2.63 ^a	39.8 ± 9.81 [#]	56.8 ± 13.8 ^{###}	46.3 ± 5.31 ^{##}
SOD (U/mg protein)	53.2 ± 10.1	19.8 ± 4.20 ^a	20.1 ± 2.03 ^a	35.8 ± 1.89 ^{b##}	42.4 ± 9.72 ^{###}	43.8 ± 13.8 ^{##}
GPx (U/mg protein)	8.96 ± 1.03	2.98 ± 0.82 ^a	5.21 ± 0.22 ^{a##}	7.35 ± 0.47 ^{b###}	8.35 ± 0.68 ^{###}	9.63 ± 1.02 ^{###}
GSH (mmol/L)	5.02 ± 0.48	2.88 ± 0.37 ^a	3.96 ± 0.88 ^{c##}	5.08 ± 0.37 ^{###}	5.51 ± 0.72 ^{###}	5.23 ± 0.39 ^{###}
TBAR (μmol/L)	27.9 ± 6.71	70.8 ± 9.42 ^a	59.3 ± 7.26 ^{a##}	33.5 ± 3.34 ^{b###}	25.3 ± 5.81 ^{###}	32.0 ± 5.02 ^{###}

Values are expressed as the means ± SD; ^a P < 0.001, ^b P < 0.01 and ^c P < 0.05) compared with Group 1; [#] P < 0.01 and ^{##} P < 0.05) compared with Group 2.

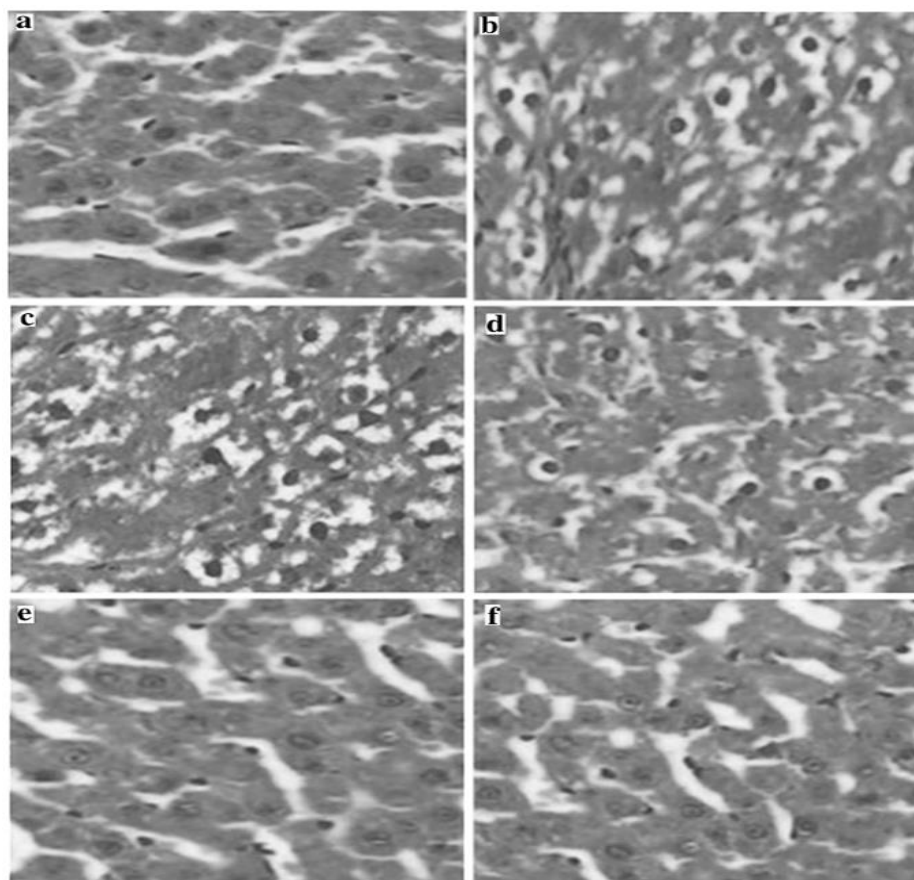


Figure 3. Photomicrographs of liver sections obtained from (a) control group, (b) CCl₄ group, (c) CCl₄ + AIPEE (100 mg/kg), (d) CCl₄ + AIPEE (200 mg/kg), (e) CCl₄ + AIPEE (300 mg/kg) and (f) positive control group (Legalon, 300 mg/kg).

and legalon was more than 1500 mg/kg.

DISCUSSION

As is shown in Table 1, the CCl₄-treated rats (Group 2) developed extensive hepatic damage, evidenced by significant increases in the levels of AST, ALT and TB of serum compared with the control group (Group 1).

Moreover, AIPEE showed dose-dependent effect on serum hepatic markers. The highest dose at 300 mg/kg caused a significant decrease in AST and ALT activities and TB level (P < 0.001) in CCl₄-intoxicated rats (Group 5). Group 5 and group 6 rats were compared with control group 1 and they showed no significant change.

From Table 2, it is shown that the levels of the hepatic oxidative stress markers CAT, SOD, GPx, and GSH in Group 2 resulted in significant decreases (P < 0.001)

compared with control Group 1. Moreover, oral administration of AIPEE showed significant and dose-dependent effect in the enzyme activities levels. Similar results were observed in the highest dose at 300 mg/kg (Group 5) compared with Group 6. It is worth noting that CAT activity was significantly higher ($P < 0.001$) in CCl_4 -treated rats after AIPEE (300 mg/kg) and Legalon (300 mg/kg) administration compared with the Group 2. As for SOD and GPx activities, we observed that the highest dose of AIPEE treatment significantly enhanced these activities ($P < 0.01$ and $P < 0.001$ for SOD and GPx, respectively), although Legalon had a stronger effect. The highest dose of AIPEE treatment led to a significant increase ($P < 0.001$) in GSH levels relative to Group 1 and Group 6, and a significant decrease in TBARS formation down to the levels similar to those observed in the control group.

The oxidative damage to cell membranes induced by CCl_4 was also associated with an increase in lipoperoxidation, as evidenced by an increase in TBARS levels and a decrease in the reduced GSH content. The GSH plays an important role in hepatoprotection, decreased GSH content is associated with oxidative stress (Ramachandra Setty et al., 2007). Post- CCl_4 treatment with 200, 300 mg/kg daily of medium and high dose AIPEE over 7 days restored the endogenous antioxidant defense system, and reversed lipid peroxidation in the liver, thereby reducing cell damage. In this matter, AIPEE (300 mg/kg) proved equally efficient to Legalon (Table 2). The hepatoprotective effect observed suggests that the six compounds, namely eugenol (1), linolenic acid (2), 6,7-epoxy-linolenic acid (3), linoleic acid (4), oleic acid (5) and hexadecanoic acid (6), identified from the AIPEE play an important role in plasma membrane stabilization, as well as in repairing liver damage caused by CCl_4 . In this regard, our results are in agreement with other studies that have reported hepatoprotective and antioxidant effects of eugenol and fatty acids (Wang et al., 2007; Bao-zhong and Li, 2008; Zhang et al., 2007). Eugenol protects against liver injury because it protects the integrity of cell membrane by removing free radicals in the body, enhancing the activity of SOD, GSH-Px and CAT, and reducing the synthesis of MDA. Linolenic acid can increase the levels of EPA and DHA in platelets and erythrocytes, and reduce the production of arachidonic acid. At the same time, linolenic acid can prevent all kinds of organ damage by scavenging free radicals, preventing protein denaturation and nucleic acid metabolic disorder and protecting the biological membrane. Eugenol has antioxidant activity, which is directly related to the hydroxyl and terminal double bond in its structure. Therefore, the presence of eugenol and fatty acids in AIPEE could contribute to its overall antioxidant and hepatoprotective activity.

Exposure of the liver to CCl_4 triggers a series of events that deregulate cell functions and affect the levels of the endogenous enzymatic antioxidant system, which

consists of CAT, SOD, and GPx (Yeum et al., 2009). The significant decrease in the activities of CAT, SOD, and GPx observed upon CCl_4 treatment is also reversed by high dose AIPEE, which restores the enzyme activities to their control values. Furthermore, GSH levels in group 5 were also significantly increased compared with those in groups 1 and 6. These results further support our finding that this extract attenuates hepatic injury in CCl_4 -treated rats.

Figure 3 shows representative photomicrographs of livers obtained from different treatments. In the control group, the structure of the hepatic lobule was clear; the cell cord was orderly, and there was no edema, fatty degeneration or visible lesions; the hepatic sinusoid was normal and the nuclear structure was clear (Figure 3a). However, in CCl_4 -treated rats (Group 2), the normal structure and most of the hepatic sinusoid had disappeared. Furthermore, hepatocytes exhibited extensive vacuolar degeneration (Figure 3b). Pre-administration of AIPEE and silymarin exerted a protective effect against CCl_4 -induced nuclear damage (Figure 3c to f). The overall liver histoarchitecture in the highest dose at 300 mg/kg was similar to that of the control and the CCl_4 /Legalon-treated animals.

As is shown in Figure 3b, the liver damage induced by CCl_4 was developed, which revealed cellular correlates of damage 24 h after CCl_4 administration. This hepatocellular injury led to an increase in liver weight. Rupture of cellular membranes resulted in intracellular content leakage with concomitant elevation of blood hepatic serum markers. Therefore, serum levels of AST, ALT, and TB, which are established indicators of liver injury, were elevated. AIPEE administration induced histologic and biochemical changes reflecting liver recovery toward normality. Analogous results has been reported under similar experimental conditions (Khan et al., 2007; Megahed et al., 2010; Talwar et al., 2013).

CONFLICT OF INTERESTS

The authors have not declared any conflict of interests.

ACKNOWLEDGMENTS

This work was supported by the Science and Technology Major Project of Inner Mongolia Mongolian medicine in China (No. GCY20150712) and Graduate Research Innovation Projects of Inner Mongolia (No. B20161013601).

REFERENCES

- Bao-zhong Z, Lin L (2008). Influence of alpha-linoleic acid plus antioxidant agent on drosophila life and mouse antioxidation ability. *ZHONGGUO ZUZHONG GONGCHENG YANJIU YU LINCHUANG KANGFU*, 12(7): 1264-1267.
- Das S, Vasishat S, Snehlata R, Das N, Srivastava LM (2000).

- Correlation between total antioxidant status and lipid peroxidation in hypercholesterolemia. *Curr Sci. Bangalore* 78(4):486-487.
- Deng XH, Zhang CJ, Wu Y, Qin LP (2013). Chemical Constituents of Whole Plant of *Veronicastrum axillare* (Sieb. et Zucc.) Yamazaki. *Chin. Pharm. J.* 48:777-781.
- Halliwell B (2012). Free radicals and antioxidants: Updating a personal view. *Nutr. Rev.* 70:257-265.
- Hu JF, Feng XZ (1999). New guaianolides from *Artemisia selengensis*. *J. Asia. Nat. Prod.* 1:169-176.
- Khan SA, Priyamvada S, Arivarasu NA, Khan S, Yusufi AN (2007). Influence of green tea on enzymes of carbohydrate metabolism, antioxidant defense, and plasma membrane in rat tissues. *Nutrition* 23:687-695.
- Liu JY, Chen CC, Wang WH, Hsu J, Yang M, Wang C (2006). The protective effects of *Hibiscus sabdariffa* extract on CCl₄-induced liver fibrosis in rats. *Food. Chem. Toxicol.* 44:336-343.
- Liu R, Dong Q, Wang XH (2010). Study on the antioxidant activity of flavonoid in *Artemisia selengensis*. *J. Sci. Technol. Food. Ind.* 31:319-21.
- Megahed HA, Zahran HG, Arbid MS, Osman A, Kandil SM (2010). Comparative study on the protective effect of biphenyl dimethyl dicarboxylate (DDB) and silymarin in hepatitis induced by carbon tetrachloride (CCl₄) in rats. *N. Y. Sci. J.* 3:1-11.
- Milena K, Carlos ABG, Gabriel AS, Naira JNB, Jorge AL, Sibeles OT, Maria GA, Marilis DM, Didier S, Obdulio GM (2014). Chemical composition, antioxidant activity and hepatoprotective potential of *Rourea induta* Planch. (Connaraceae) against CCl₄-induced liver injury in female rats. *Nutrition* 30:713-718.
- Mistry S, Dutt KR, Jena J (2013). Protective effect of *Sida cordata* leaf extract against CCl₄ induced acute liver toxicity in rats. *Asia. Pacif. J. Trop. Biom.* 3:280-284.
- Setty SR, Quereshi AA, Swamy AV, Patil T, Prakash T, Prabhu K, Gouda AV (2007). Hepatoprotective activity of *Calotropis procera* flowers against paracetamol-induced hepatic injury in rats. *Fitoterapia* 78:451-454.
- Sharma P, Bodhankar SL, Thakurdeasi PA (2012). Protective effect of aqueous extract of *Feronia elephantum* correa leaves on thioacetamide induced liver necrosis in diabetic rats. *Asian Pac. J. Trop. Biomed.* 2:691-695.
- Silva GN, Martins FR, Matheus ME (2005). Investigation of anti-inflammatory and antinociceptive activities of *Lantana trifolia*. *J. Ethnopharmacol.* 100(3):254-259.
- Singh N, Kamath V, Narasimhamurthy K, Rajini PS (2008). Protective effect of potato peel extract against carbon tetrachloride-induced liver injury in rats. *Environ. Toxicol. Pharmacol.* 26(2):241-246.
- Srivastavastava A, Shivanandappa T (2010). Hepatoprotective effect of the root extract of *Decalepis hamiltonii* against carbon tetrachloride induced oxidative stress in rats. *Food Chem.* 118(2):411-417.
- Talwar S, Jagani HV, Nayak PG, Kumar N, Kishore A, Bansal P, Shenoy RR, Nandakumar K (2013). Toxicological evaluation of Terminalia paniculata bark extract and its protective effect against CCl₄-induced liver injury in rodents. *BMC Complement. Altern. Med.* 13:127-135.
- Tu Y, Liu XH (2007). The Daur people eating-*Artemisia integrifolia*. *Chin. Folk. Ther.* 15:10-11.
- Wang BH, Zuzel KA, Rahman K, Billington D (1998). Protective effects of aged garlic extract against bromobenzene toxicity to precision cut rat liver slices. *Toxicology* 126:213-222.
- Wang JL, Zhang GF, Dong LW, Zhao M, Zhang SJ (2010). Chemical constituents in seed crust of *Syringa oblata*. *Chin. Trad. Herb. Drug.* 41: 1598-1601.
- Wang MX, Huang FH, Liu CS, Wang JW, Huang QJ (2007). Study on antioxidative effects of natural antioxidants α -ethyl linolenate. *Chin. J. Oil Crop Sci.* 29:466-469.
- Yang Q, Wang SW, Wang JB, XIE YH, LIU Z, SUN JY, MIAO S, MIAO Q (2008). Study on extraction and identification of α -linoleic acid from *Semen Zanthoxyli Bungeani*. *Chin. New Drug J.* 17:318-120.
- Yeum KJ, Beretta G, Krinsky NI, Russell RM, Aldini G (2009). Synergistic interactions of antioxidant nutrients in a biological model system. *Nutrition* 25:839-846.
- Zan LF, Bu T, Bao HY, Li Y (2008). Chemical composition in fruiting body of *Cortinarius rufo-olivaceus*. *Mycosystema* 27:284-288.
- Zhang GP, Yang JX, Zhu YA (2007). Study on antioxidant activity of *Lithospermum erythrorhizon* in vitro. *J. Wuhan Bot. Res.* 25:490-493.
- Zhang J, Li SJ, Xiang BP, He JG (2008). Modulation effects of *Artemisia integrifolia* on immune function of mice. *Food. Sci.* 29:405-408.

Related Journals:

